

Effect of Reflex Neuromodulation on an Infant with Severe Amniotic Band Syndrome: A Case Report on the use of MNRI Techniques for Physical Therapy

Isabelle Renard-Fontaine*

Bethesda Health, Center for Pediatric Development, Boynton Beach, Florida, USA

Abstract

Introduction: MNRI offers non-invasive neuromodulating techniques to activate reflex patterns which awaken the body's natural resources and support the functioning of sensory, motor, and cognitive systems.

Amniotic band syndrome (ABS) is a rare congenital disorder attributed to the anomalous amniotic bands that entangle fetal parts during intrauterine life leading to a wide range of physical abnormalities in a newborn infant, in this case, located at the superior third portion of the right arm. Due to the severity of the constricting band observed and assessed at birth, the microvascular surgeon opted for immediate post-birth surgery and Occupational and Physical Therapies were respectively initiated at 8 and 10 weeks post-surgery.

Objective: This article describes early physical therapy intervention (post-surgery) using the MNRI method and discusses the effectiveness of MNRI techniques in the recovery of arm function.

Results: Early intervention using the MNRI neuromodulation techniques with ABS disorder demonstrated new potentials and possibilities for existing therapy modalities allowing unique and faster motor milestone development. These results demonstrated voluntary motor and cognitive control of the immobile limb in an infant with ABS.

Summary: The use of the ready patterns of the brain-primary inherent reflexes can be a key method and an important cornerstone for professionals to build upon for infants with ABS.

Keywords: Masgutova neurosensorimotor reflex integration-MNRI; Amniotic band syndrome; Functional outcome in upper limb defects

Abbreviations: MNRI: Masgutova Neurosensorimotor Reflex Integration; ABS: Amniotic Band Syndrome; PT: Physical Therapy; OT: Occupational Therapy; ATNR: Asymmetrical Tonic Neck Reflex; STNR: Symmetrical Tonic Neck Reflex; R: Right; L: Left; AROM: Active Range of Motion; RUE & LUE: Upper and Lower Extremities; WFL: Within Normal Limits

Introduction

The Masgutova Neurosensorimotor Reflex Integration (MNRI) Method was developed by Dr. Masgutova from ongoing research conducted since 1989 in Russia, Poland, US and Canada based on clinic work with more than 35,000 children and adults worldwide [1,2].

The MNRI approach is built on the concept of activation of a sensory or proprioceptive stimulus for a reflex, followed by performance of the motor response associated with that reflex and all its variants in order to create a more efficient and mature neurological pathway for physical, mental, emotional and cognitive functioning [2-4].

All MNRI programs consist of the use of non-invasive natural and replicable neuromodulating techniques to activate reflex patterns. These unconditioned motor reflexes are present in the earliest stages of human development, and their motor pattern development is based on genetic motor programs typical for all humans [5-9]. The MNRI techniques have the effect of awaking the body's natural resources (the unconditioned motor reflexes) to strengthen the genetic motor memory and to support coherent functioning of sensory and motor systems [2-4,10].

Proper development and neurophysiological maturation of these primary reflexes not only support the sensory and motor systems but also cognitive, behavioral, language [1,5-7] and neuroimmunity development [11].

During individual development, these natural genetic programs expand, integrate and merge with voluntarily learned movements at the next level and become the foundation for the habituated individual sensorimotor program [1,5-7].

Amniotic band syndrome (ABS) is a rare congenital disorder that is associated with a wide range of physical abnormalities [12,13] in the newborn infant, some of which are significantly disabling and disfiguring in nature [14-16]. The commonest abnormalities usually involve the limbs and can range from simple constriction rings causing decreased blood supply to complete amputation occurring at various levels [13-15].

A number of studies estimate the incidence of ABS to be between 1 in 1300 to 1 in 15000 [16,17] births though it is not a genetic or hereditary disease, so the likelihood of its occurrence in a future pregnancy is remote [18].

The most widely accepted theory on the etiology of the condition was put forward by Torpin in 1965 [13,19] and attributes the defects to constricting action of fibrous amniotic bands (single or multiple) on fetal extremities following early rupture of the amnion with subsequent loss of amniotic fluid and extrusion of fetal parts into the chorionic cavity

*Corresponding author: Isabelle Renard-Fontaine, Bethesda Health, Center for Pediatric Development, Boynton Beach, Florida, USA, Tel: +1(561)737-7733; E-mail: isabellerenardfontaine@hotmail.com

Received February 23, 2017; Accepted February 26, 2017; Published February 28, 2017

Citation: Renard-Fontaine I (2017) Effect of Reflex Neuromodulation on an Infant with Severe Amniotic Band Syndrome: A Case Report on the use of MNRI Techniques for Physical Therapy. Int J Neurorehabilitation 4: 248. doi: 10.4172/2376-0281.1000248

Copyright: © 2017 Renard-Fontaine I. This is an open-access article distributed under the terms of the Creative Commons Attribution License, which permits unrestricted use, distribution, and reproduction in any medium, provided the original author and source are credited.

[13,17,20]. The defects are thought to result from vascular compression and resultant necrosis secondary to the compressive effect of the bands [20] with the timing of amniotic rupture and the degree of compression being determinants of the extent of abnormalities seen at birth.

Today the defects caused by ABS can be identified and studied in detail through advanced techniques such as 3D ultrasonography early in the pregnancy [12,20,21].

Bands that only cosmetically affect the skin generally do not require any intervention [18]. In the case of tight constriction bands, resulting in gross lymphedema, vascular compromise, or both, immediate surgical release is necessary [18]. The mainstay of treatment in ABS is plastic and reconstructive surgery [22]. However, in-utero surgeries are becoming increasingly popular with the advent of advanced imaging techniques [18,22]. In the event of life threatening constricting bands or threatened limb amputation, fetoscopic release of amniotic bands offers the potential to prevent limb amputation [22]. The prognosis depends on the location and severity of the constricting bands [18].

As far as treatment for ABS, multiple studies have discussed topics concerning types and outcomes of surgical interventions, but very little research is available regarding short term or long-term rehabilitation/ follow-ups [12].

Case Report

Birth and medical history

The mother of the infant of this case study was 26 years old at the time of delivery. This was her second pregnancy and a spontaneous twin gestation, [G/P: G2 P1T1 Pr0 Ab0 LC1]. She received adequate prenatal care and the majority of her prenatal labs were unremarkable. Following a premature onset of labor, the female preterm infant, twin "A", positioned in a vertex presentation, was born at 35 weeks and 4 days of gestation with a birth weight of 2.350 kg by urgent cesarean section secondary to twin "B" transverse position. Rupture of the membrane occurred at delivery and the amniotic fluid was clear. APGARS scores were 4 at 1 min and 6 at 5 min of life. The condition at delivery required bag and mask ventilation and suction. The newborn baby was transported on O₂ to the Neonatal Intensive Care Unit. She was then urgently transferred the same day to another hospital in order to provide treatment for the Amniotic Band Syndrome (Figure 1).

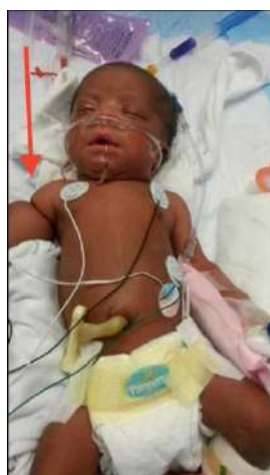

Figure 1: Infant at 1 h of life in the NICU. Right constricting band at the upper third portion of the arm prior to surgery.

The neonatologist's report at first examination described the presence of a single amniotic band at the superior third level of the right arm. There was open skin, visible bones and ligaments and no bleeding or secretions. Positioning of the right arm in adduction position resulted in infant's arm to turning blue and somewhat gray, suggesting loss of circulation. Doppler/Duplex of the extremity showed significantly damaged venous circulation. None to very limited motion in the right upper extremity was observed. The Moro response in the right arm and palmar grasp in right hand were completely absent. The medical record indicated Erb's and Klumpke's Palsy symptoms in the right upper limb. The microvascular surgeon operated immediately (day 1 of life). Surgical intervention comprised of microscopic venous anastomoses and removal of the amniotic band with leech placement. Post-op condition was complicated by apnea episode secondary to hypocardia, anemia and thrombocytopenia secondary to leech placement.

The infant was eventually discharged home 11 days after the surgery when swelling and appearance of the arm improved significantly with moderate improvement in venous return as well. AROM was only noted in the shoulder while minimal to no movement was observed in the elbow, wrist and hand. Upon discharge from the hospital, recommendations were made for outpatient based occupational and physical therapies and for follow up with a plastic surgeon.

Rehabilitation intervention

The infant was initially assessed by an Occupational Therapist at 25 days old and by a Physical Therapist at 8 weeks old. She received traditional OT/PT services for a couple of weeks without much positive response in the R arm. At that point the rehab team referred the infant to an MNRI trained physical therapist who started treating her at 10 weeks of age. Although both PT and OT services were recommended twice a week each (for 30 min sessions), the infant attended only an average of 3 sessions of each discipline per month. Her poor attendance was due to other doctor appointments, infant or twin sister illnesses, one hospitalization, transportation issues and other unknown reasons. After receiving therapy over an 8 month period, the mother discontinued bringing her daughter to therapy as a result of increasing family logistical conflicts.

The physical therapist performed an assessment of the level of development of many reflex patterns (description and scoring) according to the MNRI parameters [23] in addition to the traditional components of a physical therapy evaluation (motor skills performance, postural control, transitions skills, floor mobility, muscle tone, Muscle Manual Testing, AROM measurement, visual and auditory orientation, behavioral and sensory regulation, etc.).

The majority of the baby's reflex patterns appeared pathological or severely dysfunctional, not only caused by the main intra-uterine ABS condition but also by the whole traumatic birth and traumatic post-natal events (twin gestation, prematurity, urgent C-section, low APGAR score, respiratory distress, admission to Neonatal Intensive Care Unit, transfer to another hospital, surgery, post-surgery trauma).

Many studies have recognized the use of neurodevelopmental examination as a predictor of neuromotor outcome in premature infants; this examination includes infant primary reflex assessment. Observation of pathological reflex patterns place these infants at high risk for neuromotor issues in the future [24-28].

Therefore, physical therapy intervention, consisting of about 90% MNRI techniques, aimed at the improvement of all the identified pathological and/or dysfunctional reflexes as necessary for proper

overall motor, sensory and cognitive milestones development period. These reflexes included: Robinson Grasp, Hands Pulling, Hands Supporting, Babkin Palmomental, Spinal Perez, Spinal Galant, ATNR, STNR, Babinski, Foot Tendon Guard, Leg Cross Flexion-Extension, Bauer Crawl, Trunk Extension [1].

For the purpose of this study, only the six reflexes most directly related to the upper limb injury are being explored and listed below in Table 1. In this study, the infant demonstrated initially pathological circuits of these reflexes, severe asymmetry and wrong directionality for the motor-postural responses. Underdeveloped or dysfunctional reflexes typically cause lack of spatial orientation, poor balance and postural control, auditory perception/processing issues and overall speech delays [1,3,4,24,27].

Measures and Statistical Methods

The MNRI assessment

The primary interest of objectively assessing (scoring) the reflex patterns was to identify their measurable changes (the progress in the pattern development) for the infant with ABS. Reflex Patterns Assessments were conducted prior to (pre-test) and after (post-test) MNRI therapy sessions over an 8-month period and compared. Evaluations of motor and cognitive patterns took into consideration the child's age, neurological deficits, and status of inborn reflex patterns. Briefly, six basic reflex patterns (Diagnostic Quality Features coded X1-X6) were evaluated in each of the following five parameters: integrity of the sensory motor circuit, sequence and direction of the motor response (or movement/posture), latency (timing and speed), intensity (muscle tone regulation), and symmetry. Each parameter can earn a score from 0 to 4 depending on proper functioning of the four features specific to each parameter for a given reflex. A score of 4 indicates that all four features of the parameter are correct and a score of 0 indicates that all four features are incorrect (pathological parameter). Thus, each reflex receives a total score between 0 and 20 (5 parameters and 4 features in each) classifying the reflex pattern between pathology and high level of integration. In summary, scores ranging from 11 to 20 represent varying degrees of partially or fully integrated reflex patterns, scores from 0 to 9.99 reflect varying degrees of abnormal development, and scores of 10 to 11.99 are marginal. Scores ranging from 16 to 17.99 represent the norm [13,23,29]. Research on the Reflex Pattern Assessments was analyzed based on the multivariable function $z=f(x)$ of directly no observable phenomena, validated using an ANOVA test developed for this type of analysis (IBM SPSS Statistics Grad Pack 22.0). Results were considered statistically significant where $p<0.05$ and accepted by scientists [11,29]. Statistical evaluations of the MNRI Program were also validated with use of the Mann-Whitney U-test, using Statistical (version 6.0; Stat So Inc., Tulsa, OK, USA). P values ($M \pm SD$) less than 0.001 were considered significant and not significant at $p>0.05$ [29].

Active range of motion measurement

In this study, only active range of motion measurement of the right upper extremity joints was obtained based on the standard principles of goniometry. The chart of range of motion from the American Academy of Orthopedic Surgeon was used as the reference of normal range of motion values.

Strength assessment

Manual Muscle Testing is a procedure for the evaluation of the function and strength of individual muscles and muscle groups based on the effective performance of a movement in relation to the forces

of gravity and manual resistance [30]. According to the MMT grading system from Kendall used in this study: grade 0=no contraction felt in the muscle, grade 1=feeble contraction felt but no visible movement of the part, grade 2=moves through partial range of motion, grade 2+=moves through complete range of motion, grade 2+=moves through partial antigravity range of motion, grade 3=gradual release from test position, grade 3=holds test position (no added pressure), grade 3+=holds test position against slight pressure, grade 4=holds test position against slight to moderate pressure, grade 4+=holds test position against moderate pressure, grade 4+=holds test position against moderate to strong pressure, grade 5=holds test position against moderate to strong pressure.

Developmental skills

The Mullen Scales of Early Learning (MSEL) serve a purpose of assessing cognitive and motor ability in children ages birth through 33 months in gross motor and through 68 months in the other sections. Three out of five scales were used in this case including Gross motor, Visual Reception and Fine Motor (right upper limb). This standardized tool provides an age equivalent level of performance based on a raw score obtained for each tested area. T-scores (mean of 50 and a standard deviation of 10) are given for individual scales.

Brief review of reflex patterns in the patient

- Asymmetrical Tonic Neck Reflex (ATNR) is triggered by spontaneous head turning to one side. The limbs on the side towards which the head is rotated are extended, and the limbs of the opposite side are flexed. This reflex should be active from birth up to 4-6 months of age and mature neurologically at around 6-7 months. ATNR forms the basis for the motor abilities of the right and left sides of the body. One of its primary roles is to stimulate the vestibular-proprioceptive system including the acceleration under the influence of gravity stress and also the development of monaural and then binaural hearing. Our infant exhibited initially a pathological ATNR-with severe asymmetry and wrong direction of the response, lack of spatial orientation, poor postural control and negative compensation by other reflexes (Moro and Core Tendon Guard and Abdominal Sleep Posture). Her assessment results were: right side=1.5 points and left side=9.5 points (Table 1).
- Hands Pulling Reflex is a response to being taken by the wrists to activate sitting up movement based on sequential flexion of: 1) Elbows, 2) Head and 3) Core which is essential for development of the biomechanics of this reflex. When delayed, the head righting and neck muscle tone regulation fail to emerge. Also, a delay of this pattern negatively affects the links between the core flexion and visual convergence and trunk extension and visual divergence coordination. Ultimately, Hands Pulling creates the foundation for reaching skills with the arms, handwriting, postural control, and neck muscle tone regulation. This reflex pattern of our infant was severely asymmetrical and deeply dysfunctional at the initial assessment. Her assessment results were: right side=1.5 points and left side=6.5 points (Table 1).
- Hands Supporting Reflex is an automatic response of the arms and hands to extend forward in the direction of the ground at the moment an individual loses stable position of their body in space. This reflex integrates by 6 months of life. It influences the development of the control of the upper part of the body, grounding, and stability. It also supports formation of eye-hand coordination, close-far vision, self-defense abilities, and

Infant Reflex	10 weeks old	10 months 2 weeks old
Robinson Grasp	Severely pathological (a-reflexive) in right hand. Pre-test results: Right side=0 point, left=8 points	Pathological: very emerging minimal motor response in thumb and index finger (micro movement). Post-test results: Right side=3 points, left=12 points
Hands Pulling	Deeply dysfunctional with incorrect pattern: total absence of right elbow flexion, partial head lag, poor core flexion; improper sequence (head flexion last). Pre-test results: Right side=1.5 points, left=6.5 points	Functional pattern with appropriate head and core flexion, however pathological development of right elbow flexion. Post-test results: Right side=6 points, left=13.5 points
Babkin Palmomenta	Pathological in right hand, no signs of sensation in right palm, absence of any motor response to specific stimulation of the right hand. Motor response elicited with sensory stimulation in left hand (mouth opening and head rotation) Pre-test results: Right side=0 point, left=10.5 points	Deeply dysfunctional when right hand stimulated unilaterally. However, mouth opening and head forward flexion when stimulating both hands simultaneously. Post-test results: Right side=4.5 points, left=13 points
ATNR	Pathological bilaterally initially. Pre-test results: Right side=1.5 points, left=9.5 points	Basic pattern functional bilaterally, newly activated automaticity link between head rotation and right arm flexion; still decreased development in terms of strength, timing and symmetry. Post-test results: Right side=5 points, left=11 points
Hands Supporting	Pathological in RUE: Incorrect and severe pathology of basic pattern. Dysfunctional in LUE: Presence of some element of correct pattern. Pre-test results: Right side=0 point, left=6.5 points	RUE: Incorrect pattern/emerging functional with some correct features (good development at shoulder level, fair at elbow and poor development at wrist and hand level) LUE: Basic pattern with average development. Post-test results: Right side=5.5 points, left=10.5 points
Moro	Severely pathological: absent in RUE at birth by neonatologist's report. Pre-test results: Right side=3.5 points, left=7.5 points	Dysfunctional with emerging correct features of the basic pattern. Post-test results: Right side=6.5 points, left=9.5 points

Table 1: Changes in the level of development of selected reflex patterns before and after completing 8 months of MNRI approach based therapy.

orientation in personal space. A matured Hands Supporting reflex plays a crucial role in the elbow shock absorption that serves for efficient protection when falling down. In our patient, the right Hand Supporting pattern was deeply pathological with wrong circuit, direction, timing, intensity and asymmetry. Her assessment results were: right side=0 point and left side=6.5 points.

- Robinson Grasp Reflex is a response to stimulation of the upper part of the palm (at the base of the phalanges) by closing the palm and fingers holding them tightly while the stimulus is present. This reflex is normally reactive during the first week of life, then follows through seven developmental phases and integrates with manual abilities and skills at the end of the first year of life. In this case study, her right Hand Grasp at initial evaluation was completely a-reflexive, with severe edema, and total absence of active movement in all digits. In case of such severe pathology, grasp, toy manipulation, manual skills, and eye-hand coordination could not develop. Her assessment results were right side=0 point and left side=8 points.
- Babkin Palmomenta Reflex is triggered by pressing the middle of the palm resulting in mouth opening and the head flexing and moving down and forward. This reflex develops actively during the first months of life and integrates with “hand-mouth” coordination around the fourth month. Our infant had no response at all to stimulation of the right palm. Pathology of this pattern results in impaired hand-mouth coordination, sucking-swallowing-chewing-biting issues, speech and communication delays. Her assessment results were: right side=0 point and left side=10.5 points.

- Moro Reflex is triggered by a sudden change of the infant’s head position, usually by tilting it backward. In response, the infant opens the core of their body, extends the arms and fingers, take a deep breath in and holds it. Next, the infant closes the core by flexing the limbs, making fists and exhaling. The third part is the embracing phase when the infant finds comfort. Moro Reflex contributes to self-organization, inner control and stress management as well as positive protection and survival. Her assessment results were: right side: 3.5=points, left=7.5 points.

The assessment of the reflex development in our patient showed the necessity of physical therapy intervention for neuromodulation of her reflexes. The MNRI techniques were chosen for this purpose as this program addresses the root causes of a patient’s impairments and dysfunctions. The MNRI method offers a multitude of natural and non-invasive manual techniques specific to each reflex and their underlying functions. MNRI specialists are trained to perform these techniques in a safe and efficient manner. The ultimate effect of these techniques is the restoration and integration of the patient’s sensory, motor and cognitive nervous system and the processing/decoding functions of reflexes called in other words, neuromodulation of reflex circuits.

Results and Discussion

Level of development/integration of the reflex patterns

The results of the assessment of development/integration of the six reflex patterns mentioned above, at the beginning and after the MNRI based physical and occupational therapies, are presented in Table 1.

The first column shows that these six reflex patterns at birth were all initially pathological or deeply dysfunctional. The second column demonstrates significant improvement of every reflex pattern after 8

months of MNRI therapy. Improvements were seen with ATNR, Hands Pulling and Hands Supporting with progress from pathology toward functional development. The Babkin pattern was minimally improved from pathology to deep dysfunction and Robinson Grasp was very minimally improved as remaining pathological. The above description reflects a recovery from proximal to distal function.

The infant presented initially with a significantly atypical posturing of the upper right limb characterized by: shoulder flexion-abduction, elbow locked into hyperextension, wrist in flexion with ulnar deviation and digits into flexion (Figure 2). Per mother's report, the arm seemed "stuck" in this abnormal position eighty-five percent of the time and only rarely, some elbow flexion had been noted (most likely under the effect of gravity) through the first 10 weeks of her life. The mother had never observed her baby bringing her right hand to her mouth nor toward midline over her chest. She stated that her daughter did not appear to be aware of having a right arm.

During the very first PT session, the therapist positioned the 10 weeks old infant in left ATNR posture with head rotated to the left, left shoulder flexed and abducted at ninety degrees and elbow in extension in order to assess this reflex response (Figure 3a). As the therapist applied a gentle stretch at the left wrist with the elbow in full extension, the impaired right arm started moving and responding (Figure 3b). After few repetitions of the stimulation, an extra-ordinary event occurred as the right arm adducted and the right elbow actively flexed across chest for the first time in this infant's life (Figure 3c). Each time the therapist applied the proprioceptive input, the right elbow moved into flexion demonstrating that the MNRI techniques work beyond the muscular biomechanics with the inherent brain reflex patterns.

By the second PT session, the ATNR repatterning technique was already clearly strengthening the coordination between the work of the sensory and motor neurons within the ATNR reflex circuit. This technique

remarkably supported the neuro-rehabilitation process of the proper biomechanics function of the right arm in this case (Figure 3d).

At the end of the second session, the infant began flexing her right elbow and bringing her right arm to midline spontaneously without being triggered by the ATNR pattern (Figure 4). This was quickly followed by the infant's very first attempt to reach for a toy with her right arm. The ATNR "phenomena" in this specific case illustrates the essence of Dr. Masgutova's reflex integration concept and the clinical results when targetting the use of "the ready, genetically given brain patterns".

For the first 10 weeks of this infant's life, despite the traditional OT intervention, no evident activation of the right biceps had ever been observed; however, immediately after performing the MNRI repatterning technique for ATNR, active right elbow flexion movement repetitively occurred. This motor function was achieved by triggering inherent sensory-motor memory resources and without any direct physical inputs to the concerned arm.

Beyond the bio-mechanical aspect of this reflex pattern (automaticity links between head rotation and limb flexion on one side and limb extension on the opposite), other primary roles of the ATNR include, as it was mentioned earlier, monaural and binaural hearing, spatial orientation, and auditory processing. Shortly after repeating and reinforcing the ATNR pattern, the infant began to orient her head to sound consistently on both sides, to show improved awareness of the R side and to reach for toys placed at her side using newly acquired appropriate eye-hand coordination.

Based on the brief description of the Hands Pulling Reflex pattern earlier, it is easy to understand how this sensory-motor reflex circuit is supporting the biomechanics of the upper extremities and in particular how this pattern includes the elbow flexion part of it. Because of the existing genetic encoded links between "elbow flexion→head

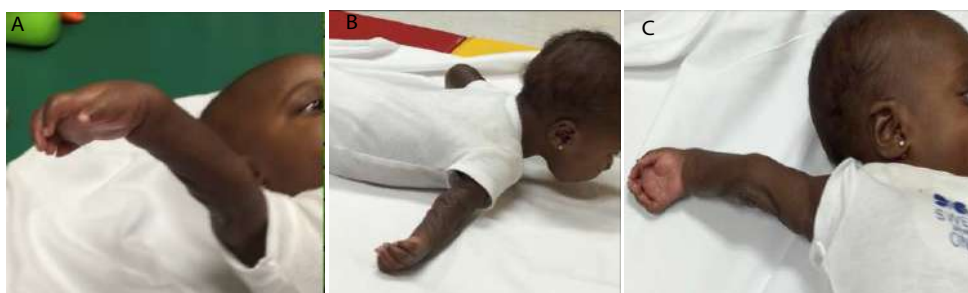

Figure 2: (a-c) Abnormal right upper limb posture into shoulder flexion-abduction, elbow hyperextension and wrist flexion with ulnar deviation, digits in flexion.

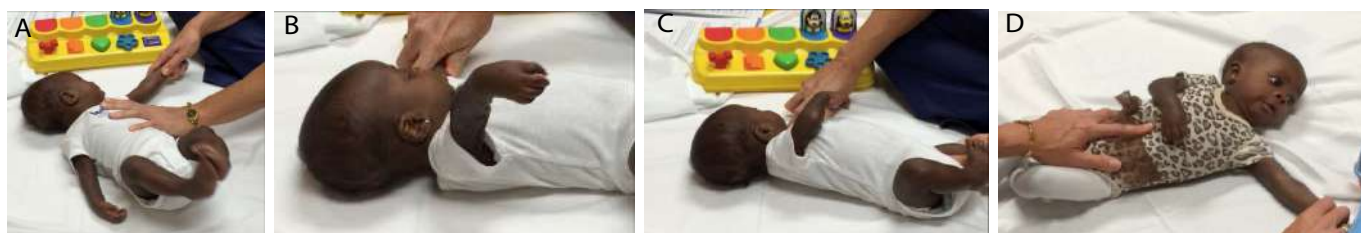

Figure 3: a Infant (10 weeks old) placed into ATNR posture, head rotated to left, left arm in ninety degrees of flexion and abduction, elbow in extension, therapist about to apply a gentle stretch at L wrist.
b: Therapist performing left ATNR repatterning technique and right arm starting reacting and responding to the stimulation.
c: Therapist performing left ATNR repatterning technique followed by the right elbow actively flexing across chest.
d: Left ATNR repatterning strengthening the coordination between the sensory and motor neurons as repeating the technique. Right elbow flexion becoming consistent.

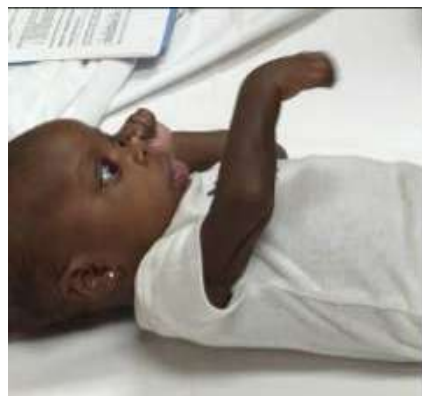

Figure 4: Spontaneous elbow flexion without triggering ATNR.

flexion→core flexion” in a pre-determined sequence, it is advantageous to work within the Hand Pulling reflex pattern. It recruits the activity from the intact/correct components of the pattern aiming at re-activating the impaired elements of the pattern.

More concretely in this case study, with the goal of restoring the right biceps muscular activity in mind, the MNRI technique uses 1) the sensory system via stimulation around the lateral aspects of both wrists 2) the head righting system 3) core flexion 4) and all the components of the left intact arm in order to activate her right elbow flexion. This modality contrasts with a standard physical therapy approach focusing strictly on the motor aspect of the right biceps. MNRI involves the whole sensory system↔brain processing↔motor system circuit [3] as innate resources of the nervous system. It provides significantly more possibilities for correction, recovery, or new development of the specific active elbow flexion function. This is one of the reasons the author believes that MNRI techniques are superiorly effective.

The pictures below (Figures 5a and 5b) illustrate how the Hands Pulling pattern improved in 2 weeks in terms of head flexion. Stagnant photos do not allow us to visualize the intensity of active elbow and core flexion, however, gradual gains in biceps and core strength were documented as we worked with her Hands Pulling Reflex (Figures 5a-5e).

Beyond the biomechanical aspect of this reflex pattern (activation of sitting up movement), as a result of a more mature Hands Pulling Reflex (Figures 5c-5e), the infant demonstrated emerging reaching skills with her right hand, emerging Babkin response in her right hand, hand to mouth movement (Figure 16), improved Head Righting in the sagittal/dorsal plane, core flexion→visual convergence (Figure 5b) and

trunk extension→visual divergence coordination (Figure 5d).

Based on the above brief description of the Hands Supporting Reflex pattern, clearly this sensory-motor reflex circuit supports the biomechanics of the upper extremities including the elbow extension part of it. Similarly to Hands Pulling, because of the existing genetic, natural link between “arm extension/hand opening” towards the supportive surface and the instinctive need for protection at the moment of losing stability of the body in space, it is more effective to work within the whole Hands Supporting pattern; it allows to recruit the activity of all the intact/correct components of the pattern in order to reactivate the impaired elements of the pattern.

With the goal of restoring the right triceps muscular activity in mind, the MNRI technique uses: 1) the sensory system via stimulation at the bottom of the palm of the hands 2) the proprioceptive system via loss of a stable vertical position 3) the motor response of the proximal control (less damaged shoulder) of the right arm 4) and all the components of the left intact arm. This modality differs from a typical physical therapy approach focusing on the isolated motor aspect of the right triceps muscular system.

Just like for any other reflex pattern, the MNRI program involving the whole sensory system- brain processing→motor system circuit as pre-existing resources of the neurologic system results in better and faster positive gains. The strength in the right triceps increased from grade 0 to grade 3+, before and after MNRI intervention.

The pictures (Figures 6a-6c) illustrate the therapist working on Hands Supporting repatterning. The infant made substantial progress from a pathological response (no triceps activation at all) in the right arm at initial assessment to an emerging functional pattern with good proximal development and significant triceps activation after therapy (Table 1). Note that Hand Supporting in her left arm improved significantly as well.

As a result of neuro-facilitation of the reflex pattern, the Hands Supporting Reflex became gradually more mature allowing this infant to reach many other motor milestones. This is where the bridge between Reflex Integration and sensory-motor function resides. It also explains why neurologists use the term “neuromodulation” when they characterize the MNRI effect [29]. Important roles of Hand Supporting include development of stability, grounding, and gravity responses. Photos in Figures 7a-7c demonstrate evident changes with postural control in a prone position on elbows, starting proximally at the shoulder level.

One other major purpose of Hands Supporting is protection, ability to break a fall and shock absorption in elbows. The infant’s progress with the Parachute response in this study was very significant as well.

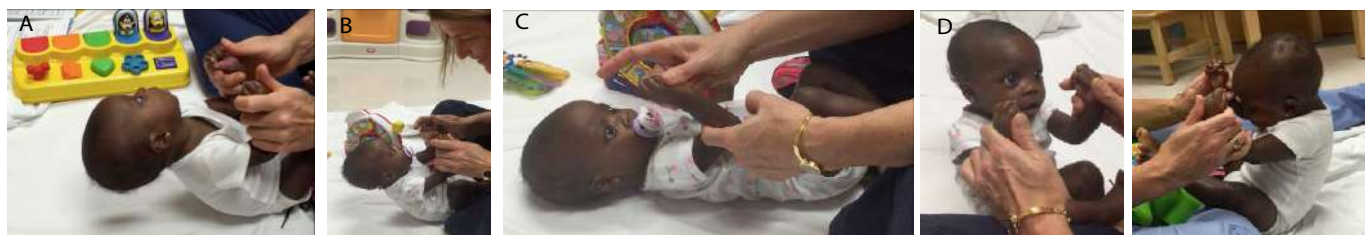

Figure 5: a: Hands Pulling at 10 weeks of age, delayed head righting, poor core flexion→visual convergence. b: Hands pulling at 12 weeks of age with improved head righting and core flexion-eye convergence. c: Showing Hands Pulling repatterning technique. d: Core flexion→visual convergence/divergence activated with Hands Pulling repatterning. e: Improved Hands Pulling with activation of right elbow flexion and core flexion in 2 sessions.

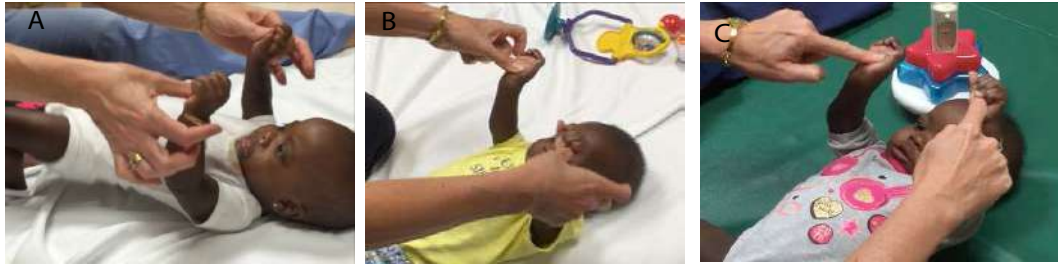

Figure 6: (a-c) Hands Supporting repatterning technique (at 7, 8 and 9 months): Therapist applying pressure in the direction of the mat. For the first time at 7 months, infant was able to actively resist therapist's input and sustain both arms up in a vertical position.

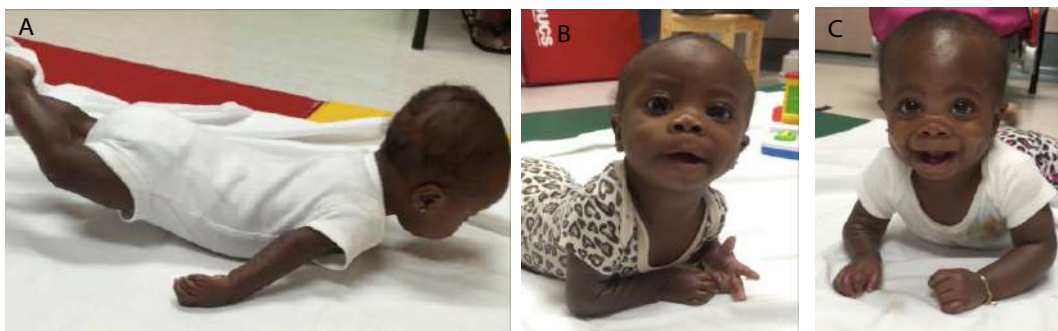

Figure 7: a: Prone at 10 weeks of age, decreased head elevation for age, poor center of gravity placement, poor elbow support, and lack of symmetry in bearing the body weight.
b: Prone at 5 months of age, more symmetrical weight bearing through elbows, significantly improved head elevation, center of gravity placement and grounding.
c: Prone at 7 months of age showing better stability, more mature base of support and improved head elevation.

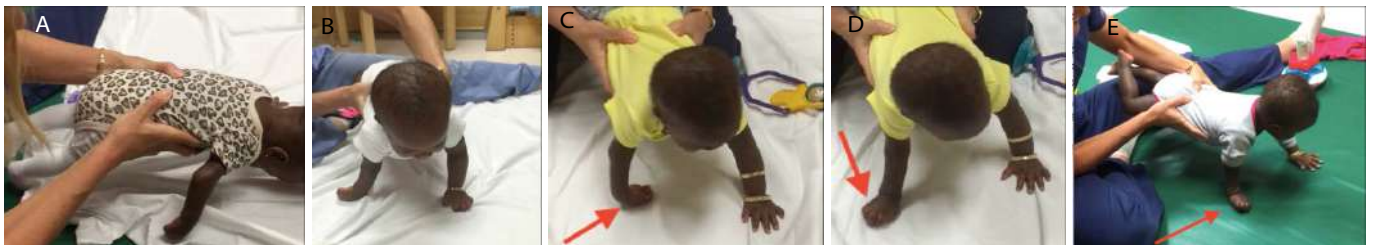

Figure 8: a: Parachute at 5 months old: inefficient, only minimal and significantly delayed right shoulder flexion triggered with poor head righting in sagittal plane.
b: Parachute at 7 months old, improved head elevation, proximal control but persistent lack of elbow shock absorption and poor wrist/hand placement.
c: Parachute at 8 months old with functional shoulder and elbow control, poor hand placement.
d: Parachute at 8 months old, first time with active wrist extension and functional hand placement.
e: Parachute at 9 months old, active wrist extension and functional hand placement thirty percent of the trials.

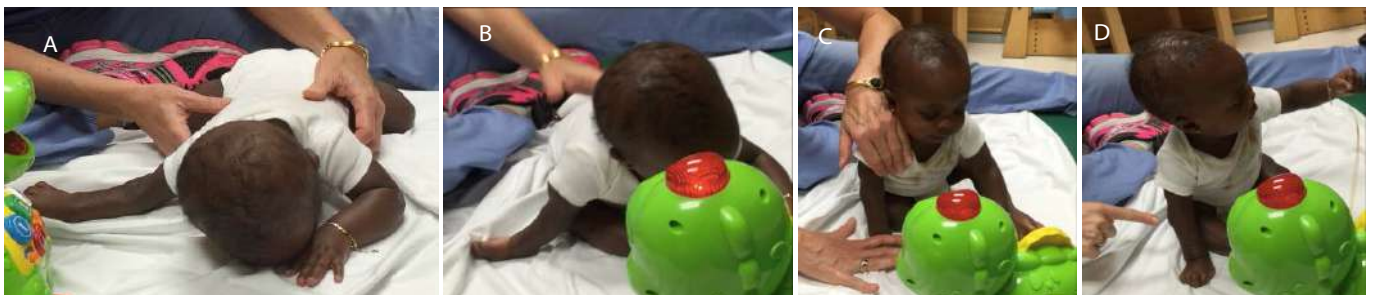

Figure 9a: Unsuccessful propping on right hand, 7 months old.
b: Emerging propping on right hand at side, 7 months old.
c: Hand Supporting-Hand Pulling combined technique.
d: Successful independent propped side sit at 7 months old.

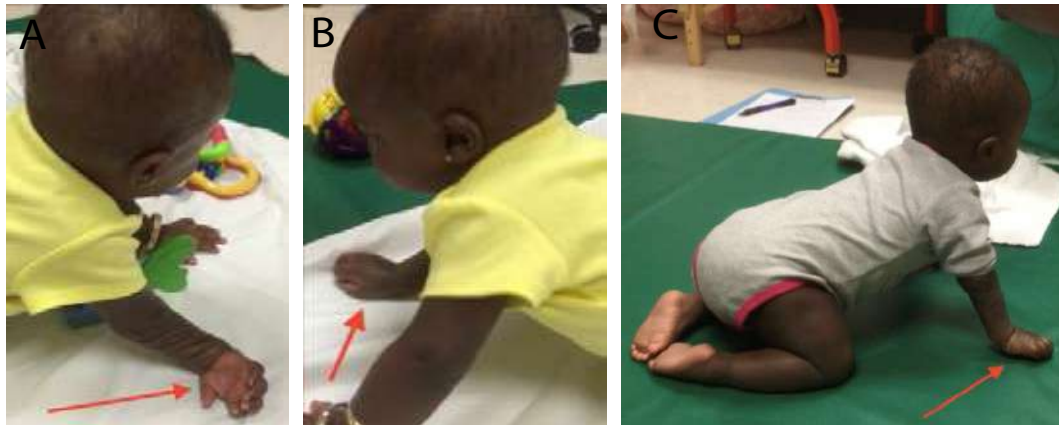


Figure 10a: Transition from sitting to quadruped and vice versa, poor hand placement.
b: Transition from sitting to quadruped with better hand placement.
c: Quadruped and eventually creeping emerged between 8 and 9 months as hand supporting (in combination with other reflex patterns) reached a higher level of maturation.

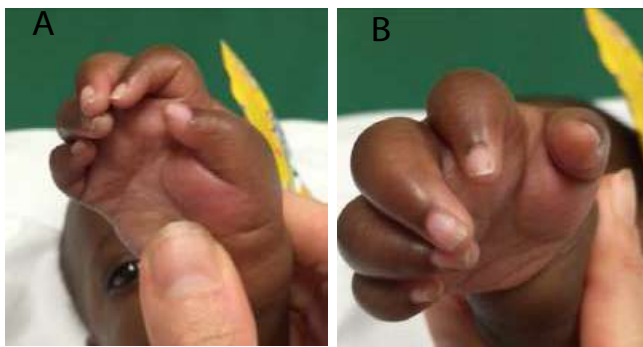


Figure 11a: Flaccid and edematous right hand and five digits, with contracture of all proximal inter-phalangeal joints in flexion.
b: Pathological Babkin and pathological Robinson Grasp (areflexive right hand).

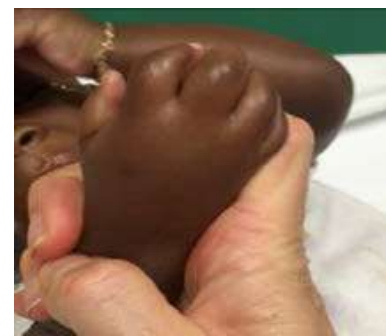

Figure 13: Robinson Grasp sensory stimulation.

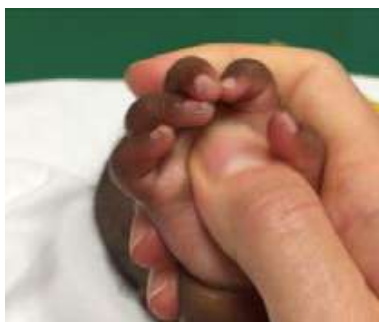

Figure 12: Babkin sensory stimulation.

Figures 8a-8e show the differences in the motor response at 5, 7, 8 and 9 months of age.

Below are other examples of the Hands Supporting Reflex as it is incorporated into functional gross motor/ transitional skills. Figure 9a through 9d show the infant's progression learning propped side sitting posture. After providing the Hand Pulling/Hand Supporting combined MNRI technique (Figure 9c), the infant successfully sustained weight

bearing through her right upper extremity without additional assistance for the first time at 7 months of age. Figure 10a through Figure 10c demonstrate progress of the right upper limb function and hand placement necessary for transition in and out of sitting, quadruped posture, and creeping skills (Figures 10a-10c).

In this case report, the constricting band caused the most severe damage to the most distal portion of the right upper limb. There was abnormal posture of the right wrist in flexion and radial deviation. The hand and five digits were flaccid, edematous with contracture of all proximal inter-phalangeal joints in flexion (Figure 11a).

Both Robinson Grasp and Babkin Palmomental reflex patterns were severely pathological at birth (a-reflexive) with a total absence of active movement in wrist/hand/digits (Figure 11b). A poorly developed Babkin Reflex typically causes eating issues (sucking-swallowing, biting and chewing), lack of hand-mouth coordination and also articulation issues. Thus coma leading to possible speech/communication delays. Babkin also forms the basis for ATNR. This infant never attempted to bring her right hand to her mouth until she started the MNRI Program and finally gained this ability at 9 months. Providing the neurosensorimotor modulation technique for Babkin (Figure 12) allowed for the "hand-mouth" coordination to emerge and start gradual development. From a completely absent response to the stimulation, the patient went to showing some active mouth movement and a slight head forward flexion with bilateral stimulation (both hands

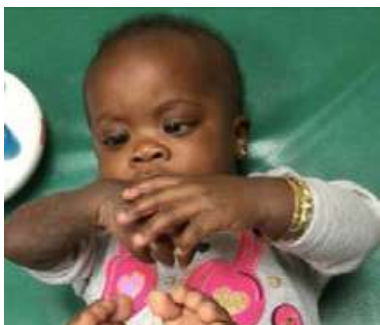

Figure 15: Staring at her own hands for the first time at 9 months.

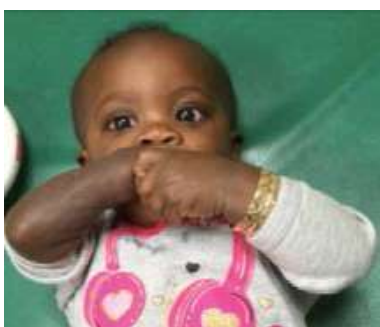

Figure 16: Hand to mouth, 9 months old.

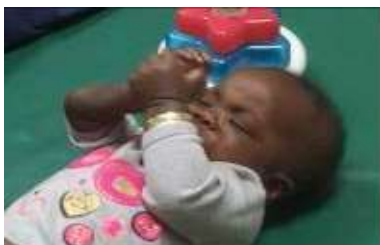

Figure 17: Bringing both hands at midline, 9 months old.

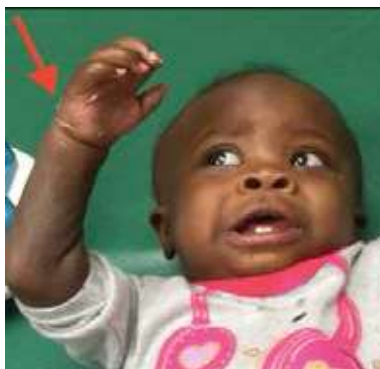

Figure 14: Awareness of her own right hand at 9 months old. Noticeable less wrist/hand drop.

simultaneously) and very minimal mouth movement was noticeable when stimulating the right palm individually.

Although the Robinson Grasp Reflex pattern remained the most



Figure 18: Bringing both hands to a toy at midline at 8 months old.



Figure 19: Hand drop, 8 months old.

challenging pattern to modulate or “re-route”, the emerging changes observed shortly prior to discontinuation of therapy suggested that the MNRI modality for Hand Grasp (Figure 13) had successfully activated the process of bringing the reflex pattern back to its genetically “given place” in the nervous system. These positive developmental changes included the new “discovery” of her own right hand (Figure 14), staring at the hand (Figure 15), bringing her right hand to her mouth (Figure 16), holding both hands at midline (Figures 16 and 17) and finally the ability to hold a toy with both hands together at midline (Figure 18).

Active range of motion and strength

Active range of motion (AROM) and strength gains in the right upper limb joints from the initial to the discharge assessment are presented in Tables 2 and 3, respectively.

The most remarkable progress in terms of AROM was noted in the shoulder in all directions and in both, elbow flexion and extension. Emerging active wrist extension was beginning to be observed just prior to discontinuation of therapy. Only micro movements in the thumb emerged but there was no active movement in any other digits yet.

The Masgutova techniques differentiate from the traditional PT approach by using innate/genetic blueprint motor patterns to support and recover a specific range of motion. The techniques add the sensory component as working within a reflex triangle model [3].

In terms of strength, the most significant gains appeared to be in the elbow flexors and extensors, each improved by two and a half grades

AROM Right Upper Limb	25 days old	10 months 2 weeks old
Shoulder flexion	WFL	WNL (active reaching against gravity in supine, up to 135° in sit/high kneeling)
Shoulder extension	WFL	WNL
Shoulder abduction	WFL	WNL
Shoulder adduction	WFL	WNL (active reaching against gravity in supine at midline)
Elbow flexion	0 degrees (would only partially flex with gravity force)	0-100° in supine
Elbow extension	Locked in hyperextension	From 100° flexion to full extension
Wrist flexion	No active movement	no active movement
Wrist extension	No active movement	Emerging as seen with hand placement with parachute reaction, and quadruped/creeping
Thumb M/P/IP	No active movement	Very emerging elicited minimal hand grasp motor response
Index finger MP/PIP/DIP	No active movement	Very emerging elicited minimal hand grasp motor response
3 rd digit MP/PIP/DIP	No active movement	No active movement
4 th digit MP/PIP/DIP	No active movement	No active movement
5 th digit MP/PIP/DIP	No active movement	No active movement

Table 2: AROM gains in R upper limb before and after completing 8 months of MNRI based therapy.

Strength in Right Upper Limb	25 days old	6 months 3 weeks	10 months
Overall shoulder	Grade 2	Grade 2	Grade 4-
Elbow flexion	Grade 0	Grade 0	Grade 3-
Elbow extension	Grade 0	Grade 1	Grade 3+
Wrist flexion	Grade 0	Grade 0	Grade 0
Wrist extension	Grade 0	Grade 0	Grade 2-
Overall hand/digits	Grade 0	Grade 0	Grade 0 emerging trace

Table 3: Strength gains in right Upper Limb (based on the standard MMT grading system): OT/PT initial assessment at 25 days old, OT re-assessment at 6 months and 3 weeks, PT assessment at discharge at 10 months after 8 months of MNRI therapy.

followed by a one and a half grade improvement in the shoulder and the wrist extensors.

Until 8 months of age, a significant right hand drop was observed for the majority of the time (Figure 19) as a result of poor wrist extensor activation. However, between 8 and 9 months of age, the therapist noticed less hand drop and occasionally the wrist in neutral alignment with the forearm, against gravity, suggesting some gradual recovery of active wrist extension (Figure 14).

Gross motor/fine motor/visual reception skills

This article only mentioned a few motor milestones that were achieved successfully (prone on elbows, propped side sitting, transition in/out of sitting, quadruped, creeping); however our therapeutic intervention's objectives included many other functional skills such as crawling, kneeling, squatting, trunk righting, visual coordination, etc. The level of performance in Fine motor, Gross motor and Visual reception areas were measured using the Mullen Scales of Early Learning. This tool provides an age equivalent level of performance based on a raw score.

Results presented in Table 4 reflect the gains over the course of the MNRI therapeutic intervention in the 3 areas mentioned above. Note that due to her history of prematurity, an adjusted age (AA), which

equals to the chronological age (CA) minus the number of weeks of prematurity, was considered to calculate the T-score. Mean is 50 and 10 represents one standard deviation.

At the time therapy was discontinued and based on the adjusted age, a T-score of 37 in gross motor area reflected a moderate delay (~1 and a half standard deviation below the mean) and a T-score of 43 in the visual reception reflected a mild delay (less than 1 standard deviation below the mean). As expected, the fine motor performance (for the right upper limb) appeared profoundly delay, however it was observed that proximal recovery was necessary prior to the emergence of distal restoration. The most remarkable changes in the wrist and hands happened within the last month prior to discontinuing therapy.

Conclusion

The overall outcome of this case study is remarkable considering the rare congenital condition from which this infant suffered. A severe prenatal anatomical-neurological damage causing poor expression of many of her primary reflexes at birth. In addition, it must be taken into consideration the incredible amount of trauma this newborn endured during and immediately after birth.

While this patient still has a long road to recovery, especially in terms of distal control (wrist and hand/fingers functions), her

Mullen Scale	CA: 25 days AA: 38 weeks of gestation	CA: 2 mo AA: 2 weeks	CA: 6 mo 3 weeks AA: 5 mo 2 weeks	CA: 10 mo 2 weeks AA: 9 mo
Gross motor	Not tested	RS:3 AE: 1 mo T-score: 48	Not tested	RS: 11 AE: 8 mo T-score 37
Fine Motor (RUE)	RS: 0 AE: N/A	Not tested	RS: 0 AE: N/A	RS: 3 AE: 1 mo T-score: <20
Visual Reception	RS:1 AE:1mo T-score: 30	Not tested	RS:7 AE:5mo T-score: 45	RS: 11 AE: 7 mo T-score: T-score 43

RS: Raw Score; AE: Age Equivalent; T-score (M=50, SD=10). CA: Chronological Age; AA: Adjusted Age

Table 4: Changes in gross motor, fine motor and visual reception skills according to the Mullen scales of early learning.

significant progress over such a short period of time has been more than encouraging. She was transformed from a neonate with a totally functionless, swollen right upper limb to an active infant exhibiting independent transitions, floor mobility, the ability to protect her-self using the Parachute response and some emerging functional use of the right upper limb. She has clearly demonstrated a gradual restoration of her right upper limb function from proximal to distal and it can be anticipated that this progression will continue with proper intervention over time. Her results in the development of her reflex patterns within this short time show the possibilities for ongoing development leading ultimately to the acquisition of further milestones.

The increased level of reflex integration maturation of the infant in the study, based on the neuromodulation therapeutic approach, shows evident correlation with concurrently performed functional motor skills standardized test, Manual Muscle Test and AROM measurements. In other words, all of the above tests have reinforced the concept that a strong direct link exists between reflex integration and functional development.

Physical and Occupational Therapists traditionally focus on either the sensory system or the motor system separately but they are generally not trained to combine both. Neither discipline uses the strong pre-existing, genetic specific sensory-motor association within the neuromodulation concept of a reflex circuit components and integration of its biomechanics with its main protective function (i.e. training of the Parachute pattern or STNR for the development of postural control in quadruped and creeping).

Aiming at the restoration of neurophysiological and sensory-motor aspects of a basic reflex pattern and/or their variants in cases where they are dysfunctional, immature or unintegrated, builds the foundation for future neurodevelopment and strengthening of the relevant nerve network.

MNRI modalities and traditional physical/occupational therapies share the same ultimate goals of restoring neurological function. The additional highly effective component of MNRI however resides in going back to the "pure" innate form of a reflex motor pattern, allowing for the brain to recognize a template for growth and development supplied by its genetic inheritance. The particular example of how the genetically programmed ATNR reflex pattern was used in order to re-activate the physiological circuit of the right elbow flexion reflects the obvious effectiveness of MNRI concepts and proves the power of innate resources.

Once studying the profile of reflex patterns and then finding/analyzing the links between reflexes and gross/fine motor skills, the MNRI program becomes an incredibly effective and reliable tool to enhance the possibilities of a child to recover or develop optimal sensory-motor functions.

References

1. Masgutova S (2007) Integration of infant dynamic and postural reflex patterns: Masgutova neuro-sensory-motor and reflex integration-MNRI method for children and adults. SMEI, Orlando, USA.
2. Masgutova S (2011) Infant dynamic and postural reflexes. SMEI, Orlando USA.
3. Masgutova S, Masgutov D, Akhmatova N, Akhmatov E (2015) Neurophysiological foundation of the MNRI reflex integration program. In: *Reflexes: Portal to neurodevelopment and learning*, pp: 31-40.
4. Masgutova SK (2006b) Infant Reflex Integration in Movement Development. In: Masgutova SK, Regner A, Ronin- al nows a MDE (Eds.) *Materials of polish national conference: Modern methods of stimulation of movement development and learning in children with dif culties in learning, ADHD and Autism*. Pomorska Medical Academy, Szczecin, Poland.
5. Pavlov I (1960) *Conditioned reflexes: An investigation of the physiological activity of the cerebral cortex*. Dover Publications Inc., New York, USA.
6. Sherrington CS (1947) *The integrative action of the nervous system*. Cambridge University Press, London, UK.
7. Anokhin PK (1973) *Biology and neurophysiology of the conditioned reflex and its role in adaptive behavior*. International series of Monographs in Cerebrovisceral and Behavioral Physiology and Conditioned Reflexes, USA.
8. Vygotsky L (2012) *Thought and language*. MIT Press books, Cambridge.
9. Luria AR (1978) *Functional brain organization*. In: Smirnov AA, Luria AR, Niebilistsin VD (Eds) *Biological-scientific basis of psychology*. Moscow, Russia.
10. Pilecki W, Masgutova S, Kowalewska J, Masgutov D, Akhmatova N, et al. (2012) The impact of rehabilitation carried out using the masgutova neurosensorimotor reflex integration method in children with cerebral palsy on the results of brain stem auditory potential examinations. *Adv Clin Exp Med* 21: 363-371.
11. Masgutova SK, Akhmatova NK, Lebedinskava OV (2013) Clinical-immunological assessment of therapy effect of the neuro-sensory-motor integration program of reflex patterns in airway chronic inflammatory diseases. *Front Immunol*, Switzerland.
12. Samra S, Samra AH, Netscher DT (2006) Threatened lower extremity in a neonate from a severely constricting amniotic band: A case for limb salvage after a 6 year functional follow-up. *Ann Plast Surg* 57: 569-572.
13. Cignini P, Giorlandino C, Padula F, Dugo N, Cafà EV, et al. (2012) Epidemiology and risk factors of amniotic band syndrome or ADAM sequence. *J Prenat Med* 6: 59-63.
14. Burk CJ, Aber C, Connelly EA (2007) Ehlers-Danlos syndrome type IV: keloidal plaques of the lower extremities, amniotic band limb deformity and a new mutation. *J Am Acad Dermatol* 56: S53-54.
15. Dodampahala SH, Dodampahala SK, Dodampahala SD, Meegahawatta AR (2015) Amniotic band syndrome-case report of a rare congenital condition causing undue suffering through delayed diagnosis. *IJSR* 4: 451-453.
16. Poeuf B, Samson P, Magalon G (2008) Amniotic band syndrome. *Chir Main* 27: S136-147.
17. Orioli IM, Ribeiro MG, Castilla EE (2003) Clinical and epidemiological studies of amniotic deformity, adhesion and mutilation (ADAM) sequence in a South American (ECLAMC) population. *Am J Med Genet A* 118A: 135-145.
18. Radhakrishnan SA (2011) Amniotic band syndrome (ABS): A review. *Asian J Nur Edu Res* 1: 41-44.
19. Torpin R (1965) Amniochorionic mesoblastic fibrous strings and amniotic bands: Associated constricting fetal malformations or fetal death. *Am J Obs Gynecol* 91: 65-75.
20. Nardoza LMM, Araujo E, Caetano ACR, Moron AF (2012) Prenatal diagnosis of amniotic band syndrome in the third trimester of pregnancy using 3D ultrasound. *J Clin Imaging Sci India* 2: 22.
21. Marino T (2004) Ultrasound abnormalities of the amniotic fluid, membranes, umbilical cord and placenta. *Obstet Gynecol Clin North Am* 31: 177-200.
22. Shetty P, Menezes LT, Tauro LF, Diddigi KA (2013) Amniotic Band Syndrome. *Indian J Surg* 75: 401-402.
23. Masgutova S, Masgutov D (2015) MNRI® assessment for determining the level of reflex development. In: *Reflexes: Portal to neurodevelopment and learning*. A collective work, SMEI: Orlando, USA.
24. Paine RS (1964) The evolution of infantile postural reflexes in the presence of chronic brain syndromes. *Dev Med Child Neurol* 6: 345-361.
25. Marilee CA, Capute AJ (1989) Neonatal neurodevelopmental examination as a predictor of neuromotor outcome in premature infants. *Pediatrics* 83: 498-506.
26. Lano A (2002) The value of neonatal neurological assessment in predicting neurodevelopmental problems at pre-school age. University of Helsinki, Finland.
27. Godbole K, Barve S, Chaudhari S (1997) Early predictors of neurodevelopmental outcome in high risk infants. *Indian Pediatr* 34: 491-495.
28. Sohn M, Ahn Y, Lee S (2011) Assessment of primitive reflexes in high-risk newborns. *J Clin Med Res* 3: 285-290.
29. Koberda JL, Akhmatova N, Akhmatova E, Bienkiewicz A, Nowak K, et al. (2016) Masgutova neurosensorimotor reflex integration (MNRI) neuromodulation technique induces positive brain maps (QEEG) changes. *J Neurol Neurobiol* 2:1-2.
30. Wintz MM (1959) Variations in current manual muscle testing. *Phys Ther Rev* 39: 466-475.